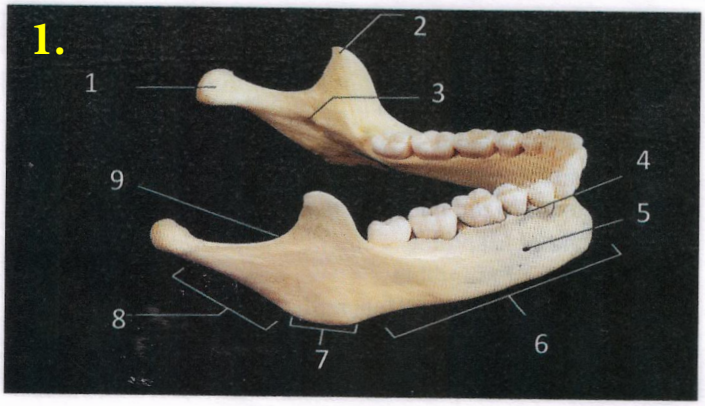
1.
1
2
3
4
5
6
7
8
9

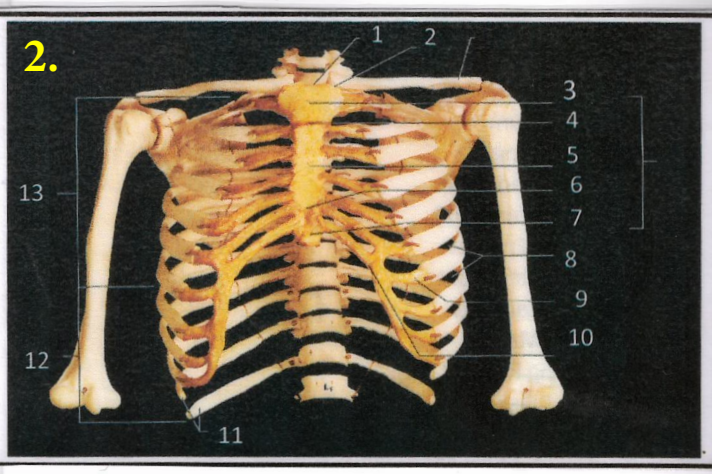
2.
1
2
3
4
5
6
7
8
9
10
11
12
13

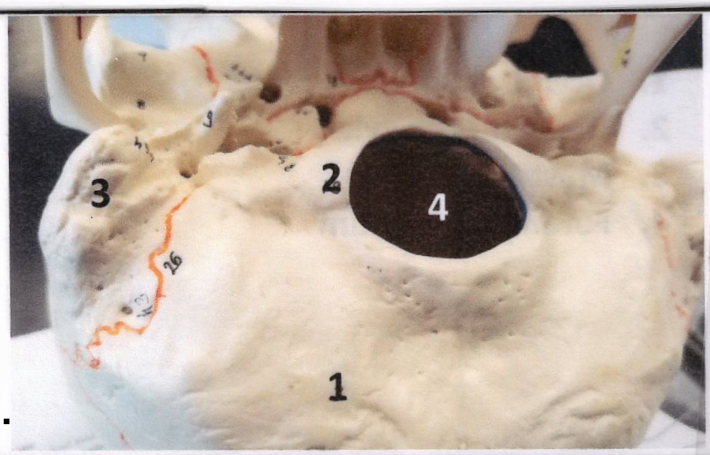
3.
1
2
3
4

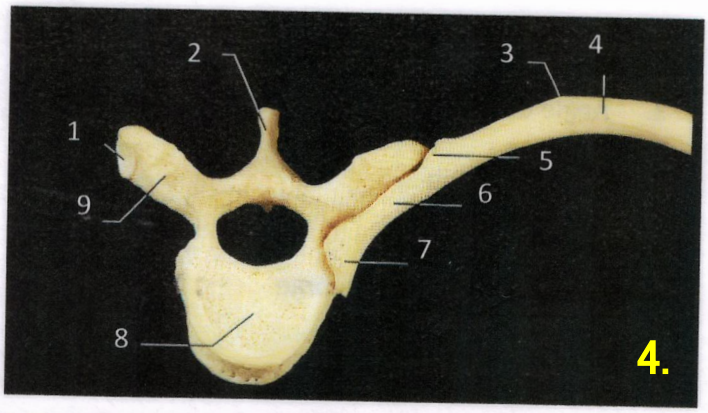
4.
1
2
3
4
5
6
7
8
9

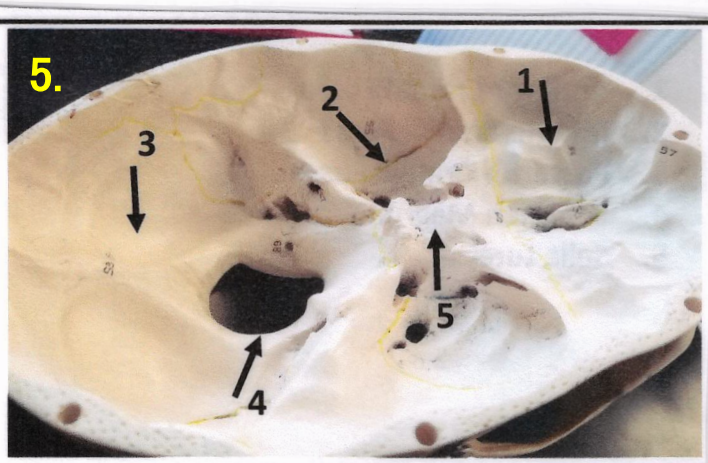
5.
1
2
3
4
5

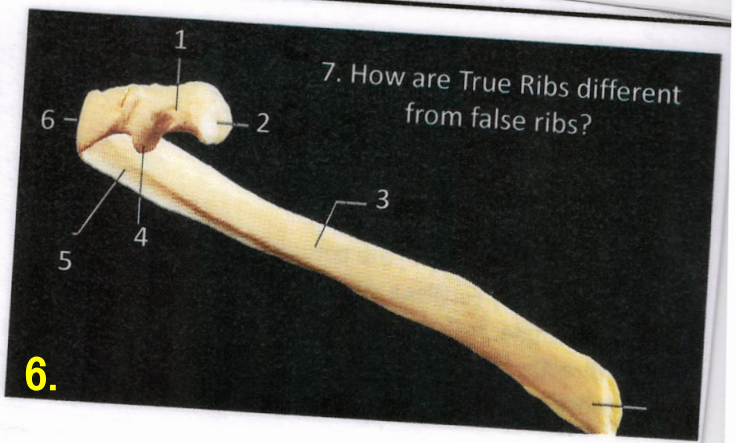
6.
7. How are True Ribs different from false ribs?
1
2
3
4
5
6

2.

1. Jugular Notch
2. Clavicular Notch
3. Manubrium
4. Sternal Angle
5. Body (Gladiolus)
6. Xiphisternal Joint
7. Xiphoid Process
8. Intercostal Spaces
9. Costal Cartilage
10. Costal Margin
11. Floating Ribs (11-12)
12. False Ribs (8-12)
13. True Ribs (1-7)

1.

1. Mandibular Condyle
2. Coronoid Process
3. Mandibular Foramen
4. Alveolar Margin
5. Mental Foramen
6. Body of Mandible
7. Angle of Mandible
8. Ramus of Mandible

Mandibular Symphisis (Unlisted): Line of fusion between two lateral halves of mandible. Fuses in early childhood.

1. Transverse Costal Facet (For tubercle of rib)
2. Spinous Process
3. Angle of Rib
4. Shaft
5. Tubercle of Rib
6. Neck of Rib
7. Head of Rib
8. Body of Thoracic Vertebrae

4.

3.

1. **Occipital Bone**
2. **Occipital Condyle**
3. **Mastoid Process**
4. **Foramen Magnum**

6.

1. Neck of Rib
2. Head of Rib
3. Shaft of Rib
4. Tubercle of Rib
5. Costal Groove
6. Angle of Rib
7. True Ribs (ribs 1-7) are connected to sternum directly by cartilage. True ribs tend to have a hook like angle. False ribs (ribs 8-12) are not connected directly to the sternum by cartilage. Tend to be short and lack a hook.

5.

1. **Anterior Cranial Fossa**
2. **Middle Cranial Fossa**
3. **Posterior Cranial Fossa**
4. **Foramen Magnum**
5. **Sella turcica**